

# Dietary Intervention With a Targeted Micronutrient Formulation Reduces the Visual Discomfort Associated With Vitreous Degeneration

Emmanuel Ankamah<sup>1</sup>, Marina Green-Gomez<sup>1</sup>, Warren Roche<sup>1</sup>, Eugene Ng<sup>1,2</sup>, Ulrich Welge-Lüssen<sup>3</sup>, Thomas Kaercher<sup>4</sup>, and John M. Nolan<sup>1</sup>

<sup>1</sup> Nutrition Research Centre Ireland, School of Health Science, Carriganore House, Waterford Institute of Technology, West Campus, Waterford, Ireland

<sup>2</sup> Institute of Eye Surgery, UPMC Whitfield, Buttlersdown, County Waterford, Ireland

<sup>3</sup> Augenzentrum Stachus, München, Germany

<sup>4</sup> Facharzt für Augenheilkunde, Heidelberg, Germany

**Correspondence:** John M. Nolan, Nutrition Research Centre Ireland, School of Health Sciences, Waterford Institute of Technology, West Campus, Carriganore House, Waterford, X91 K236, Ireland. e-mail: [jmnolan.wit.ie](mailto:jmnolan.wit.ie)

**Received:** April 8, 2021

**Accepted:** September 5, 2021

**Published:** October 14, 2021

**Keywords:** vitreous degeneration; supplementation; randomized clinical trial; floaters; vitreous opacity areas; ImageJ; contrast sensitivity; VitroCap N

**Citation:** Ankamah E, Green-Gomez M, Roche W, Ng E, Welge-Lüssen U, Kaercher T, Nolan JM. Dietary intervention with a targeted micronutrient formulation reduces the visual discomfort associated with vitreous degeneration. *Transl Vis Sci Technol.* 2021;10(12):19. <https://doi.org/10.1167/tvst.10.12.19>

**Purpose:** To investigate the impact of supplementation with a targeted micronutrient formulation on the visual discomfort associated with vitreous degeneration.

**Methods:** In this clinical trial, 61 patients with symptomatic vitreous floaters were randomized to consume daily, the active supplement consisting of 125 mg L-lysine, 40 mg vitamin C, 26.3 mg *Vitis vinifera* extract, 5 mg zinc, and 100 mg *Citrus aurantium* or placebo for 6 months. Change in visual discomfort from floaters, assessed with the Floater Disturbance Questionnaire, was the primary outcome measure. Secondary outcome measures included best-corrected visual acuity, letter contrast sensitivity, photopic functional contrast sensitivity with positive and negative contrast polarity, and quantitative vitreous opacity areas.

**Results:** After supplementation, the active group reported a significant decrease in their visual discomfort from floaters ( $P < 0.001$ ), whereas the placebo group had no significant change in their visual discomfort ( $P = 0.416$ ). At 6 months, there was a significant decrease in vitreous opacity areas in the active group ( $P < 0.001$ ) and an insignificant increase in vitreous opacity areas in the placebo group ( $P = 0.081$ ). Also, there was a significant improvement in photopic functional contrast sensitivity with positive contrast polarity in the active group after supplementation ( $P = 0.047$ ).

**Conclusions:** The findings of this study indicate improvements in vision-related quality of life and visual function of patients suffering from vitreous floaters after supplementation with a formulation of antioxidative and antiglycation micronutrients. Notably, these improvements were confirmed by the decrease in vitreous opacity areas in the active group.

**Translational Relevance:** This targeted dietary intervention should be considered to support patients with symptomatic vitreous degeneration.

## Introduction

Vitreous fills the posterior segment of the eye and contributes to optical transparency. Degeneration of this exquisite gel is, nonetheless, ubiquitous during life, mainly resulting from aging or disease. Two principal and inter-related processes, liquefaction

(synchysis senilis) and posterior vitreous detachment (PVD), account for vitreous degeneration.<sup>1</sup> Oxidative stress, increased intravitreal proteolytic enzymes, and a decrease in vitreous antioxidant capacity have been proposed as the underlying mechanisms for these degenerative processes.<sup>2-4</sup> Aging aside, high myopia, menopause, and hereditary extracellular matrix syndromes such as Stickler syndrome and

*LAMA5* multisystem syndrome are the other known risk factors for vitreous degeneration.<sup>5–8</sup>

Vitreous degeneration culminates in vitreous floaters, the perception of linear strands and dark grey spots primarily within the central visual field.<sup>9</sup> Floaters have significant negative impact on visual function and vision-related quality of life of its sufferers.<sup>10,11</sup> It is therefore not surprising that some patients are willing to trade 1.1 years of every 10 years of their remaining life to get rid of their floaters.<sup>12–14</sup> Unfortunately, the conventional treatment mostly offered to these sufferers, after clinicians have successfully ruled out the possibilities of retinal complications after the onset of floaters, is watchful waiting. In that, patients are only monitored after they have been either reassured that their floaters will resolve with time or counselled to adapt to their new visual experience.<sup>15</sup>

Floaters do not resolve with time, contrary to the popular assertion of clinicians. This is because the increased fluidity of vitreous after degeneration and the continuous saccadic eye movements necessary for performing daily life visual activities prevent opacities from settling inferiorly within vitreous.<sup>16,17</sup> Further, Wagle and associates<sup>14</sup> have demonstrated using utility values analysis that the impact of floaters on quality of life are similar for both chronic and acute sufferers. This finding possibly explains why patients continue to seek medical intervention to their floaters from one facility to another, at the expense of doctors' advice of resolution of or adaptation to their condition.<sup>1</sup>

Aside from watchful waiting, pars plana vitrectomy and Nd:YAG laser vitreolysis are the other treatment options available. Pars plana vitrectomy remains the definitive treatment for floaters, substantiated by beneficial outcomes on objective and subjective measurements.<sup>18–20</sup> Pars plana vitrectomy for floaters, or simply floaterectomy, is increasingly being adopted by retinal surgeons in part owing to the advancement in vitreoretinal surgical instrumentation and the availability of the evidence regarding the safety of the procedure.<sup>18,21</sup> Nd:YAG laser vitreolysis is, however, described as an unconventional treatment because prospective studies assessing the long-term safety and efficacy of the procedure are lacking to date.<sup>15,22</sup> Importantly, the potential sight-threatening risks associated with these treatment options, including retinal detachments, cataract formation or progression, iatrogenic tears, vitreoretinal hemorrhage, worsening floaters, prolonged elevation of intraocular pressure, refractory open-angle glaucoma, and anesthesia-related complications (e.g., respiratory depression from retrobulbar block), deter clinicians from recommending these treatments, especially when the desired benefits do not significantly outweigh the

potential risks.<sup>20,23–27</sup> It follows from this discussion that a low-risk yet effective therapy is warranted to boost the vision-related quality of life of patients with floaters.

In terms of a low-risk yet effective therapy for floaters, a plausible idea to pursue relates to management with micronutrients that can retard the aforementioned mechanisms underpinning vitreous degeneration. This rationale derives from in vitro experimental evidence indicating the potency of exogenous micronutrients such as hesperidin, verbacosides, leucocyanidins, and L-lysine against vitreous degeneration mechanisms.<sup>28–31</sup> Given that some of these micronutrients accumulate in the human vitreous and have been shown to decrease with degeneration and disease of vitreous, we hypothesize that dietary enrichment with targeted exogenous micronutrients will decrease the visual discomfort of patients with symptomatic vitreous degeneration and improve their vision-related quality of life (Socci R, et al. *IOVS*. 1987;4:ARVO Abstract 74).<sup>4,32,33</sup> This study was therefore conducted to test the above-stated hypothesis in a randomized controlled trial fashion.

## Methods

### Study Design

The Floater Intervention Study (FLIES) is a registered (ISRCTN15605916), parallel group, single-center, double-blind, randomized, placebo-controlled clinical trial designed to investigate the impact of supplementation with an active formulation of antioxidative and antiglycation micronutrients on the visual discomfort experienced by floater sufferers. Inclusion criteria for this study included primary floaters (age related or myopia related onset) in at least one eye; 18 years and older; no cataract surgery within the duration of the trial; no neural, developmental, or retinal disease (e.g., retinal breaks or detachments, age-related macular degeneration, diabetic retinopathy, and branch retinal vein occlusion); and a best-corrected visual acuity (BCVA) of 20/40 or better. For visual function assessments conducted as part of the study, one eye was selected randomly as the study eye in patients with bilateral floaters, whereas the eye with floaters served as the study eye in unilateral cases.

### Randomization and Intervention

The Consolidated Standards of Reporting Trials (CONSORT) flow diagram of FLIES methodology is shown in Figure 1. A total of 343 patients with

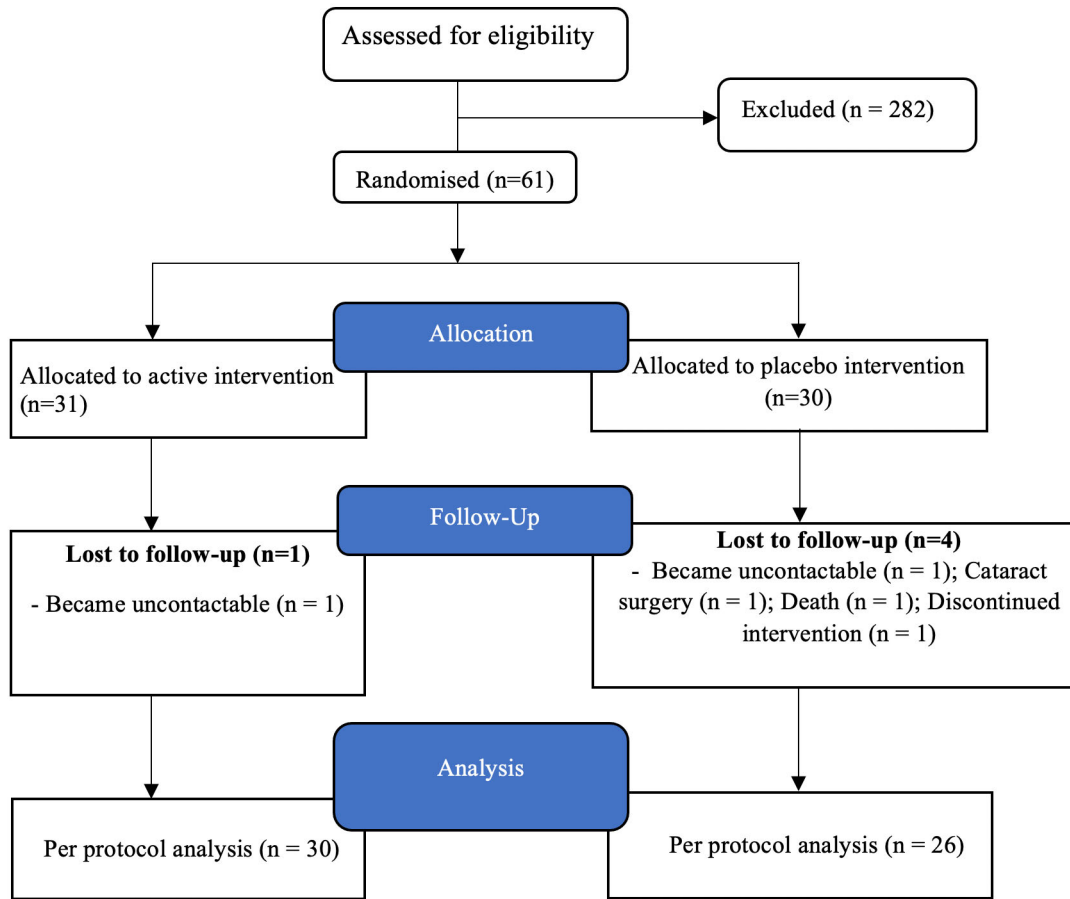


Figure 1. Consolidated Standards of Reporting Trials (CONSORT) flow diagram of FLIES.

vitreous floaters were screened for eligibility to participate in this trial. Out of these, 282 had other ocular comorbidities and failed to satisfy the inclusion criteria for the study. Therefore, 61 patients were enrolled and randomized in a 50:50 masked fashion to either the active group ( $n = 31$ ) or the placebo group ( $n = 30$ ). Randomization was performed using a customized clinical trial management software program (Trial Controller) developed by NOW-Science Consultancy Ltd, Waterford, Ireland.

The active group received a capsule containing 125 mg L-lysine, 40 mg vitamin C, 26.3 mg *Vitis vinifera* extract, 5 mg zinc, and 100 mg *Citrus aurantium* (commercially available as VitroCap N), whereas the placebo group received a placebo capsule containing microcrystalline cellulose. The active and placebo capsules were identical in shape, color, and packaging. Supplementation was via the oral route; study patients were instructed to take one capsule per day with a meal for 6 months. The study staff and patients remained masked to the group allocations throughout the study. The randomization sequence for the FLIES study was

revealed after completion of the study and masked review of the database.

## Ethics Approval

The study was approved by the Research Ethics Committee, Health Service Executive, South East, Ireland, and the Waterford Institute of Technology Research Ethics Committee, Waterford, Ireland. All assessments performed on the study patients enrolled were in accordance with the 1964 Helsinki Declaration and its later amendments or comparable ethical standards. Informed consent was obtained from all the patients before enrolment into the study.

## Assessments

### Demographic, Lifestyle, Medical, and Ophthalmic Assessment

Demographic, lifestyle, medical, and ophthalmic data were captured at baseline for all patients. Body mass index was calculated from height (in

meters) and weight (in kilogram) measurements recorded using the Leicester Height Measure and SECA weighing scales (SECA, Birmingham, UK), respectively. Smoking status was categorized into current smoker (i.e., smoked  $\geq 100$  cigarettes in lifetime and  $\geq 1$  cigarette in the last 12 months), ex-smoker (smoked  $\geq 100$  cigarettes in lifetime and none in the last 12 months) and never smoker (never smoked or smoked  $\leq 100$  cigarettes in lifetime).

**Vision-Related Quality of Life Assessment: Floater Disturbance Questionnaire**

The Floater Disturbance Questionnaire is a short, non-standardized disease-specific patient-reported outcome measure specifically designed to capture the subjective response of patients suffering from vitreous floaters as part of this study. The questionnaire comprised questions, which used polytomous response ratings, to assess the visual discomforts associated with floaters. Two questionnaire items that were used to assess the vision-related quality of life in this study, at the baseline and final visits, were the change in visual discomfort from floaters and the effect of floaters on daily life as shown below:

- a. Change in visual discomfort (baseline and final visits)
  - i. How will you describe your visual discomfort from floaters since you developed floaters? (Baseline only)

OR

- ii. Has there been a change in severity of your visual discomfort from floaters after supplementation? (Final Visit only)

My condition has been stable and I am not bothered by my floaters.  
 My floaters have been intermittently and moderately bothersome.  
 My floaters have been persistently bothersome.

The question offered a three-response choice, which were rated as follows: My condition has become stable and I have not been bothered by my floaters = 0; My floaters have been intermittently and moderately bothersome = 1; or My floaters have been persistently bothersome = 2. Patient responses were reported as simple frequency distributions.

Given a 6-month follow-up duration, we applied a weighting factor of 3 to all the responses such that a persistent disturbance throughout the 6-month study

period could be represented by a score of 6. As a result, the scoring used for this questionnaire item were 0, 3, and 6 for stable condition, intermittent disturbance, and persistent disturbance, respectively. The mean score of each intervention group for this questionnaire item was attained by simple summation and averaging of responses of patients in the respective groups. A mean score of 3 signified a moderate severity of floaters, with increasing severity denoted by a progress towards a score of 6. A paired samples *t*-test was conducted for each intervention group to assess the change in discomfort from floaters after supplementation. The percentage of patients who reported a desired therapeutic effect (of decrease in floater suffering) were also assessed.

- b. Effect of floaters on daily life (baseline and final visits)

This questionnaire item used a 5-point rating scale to assess the effect of floaters on the daily life of patients:

How would you describe the effect of floaters on your daily life in the past week?

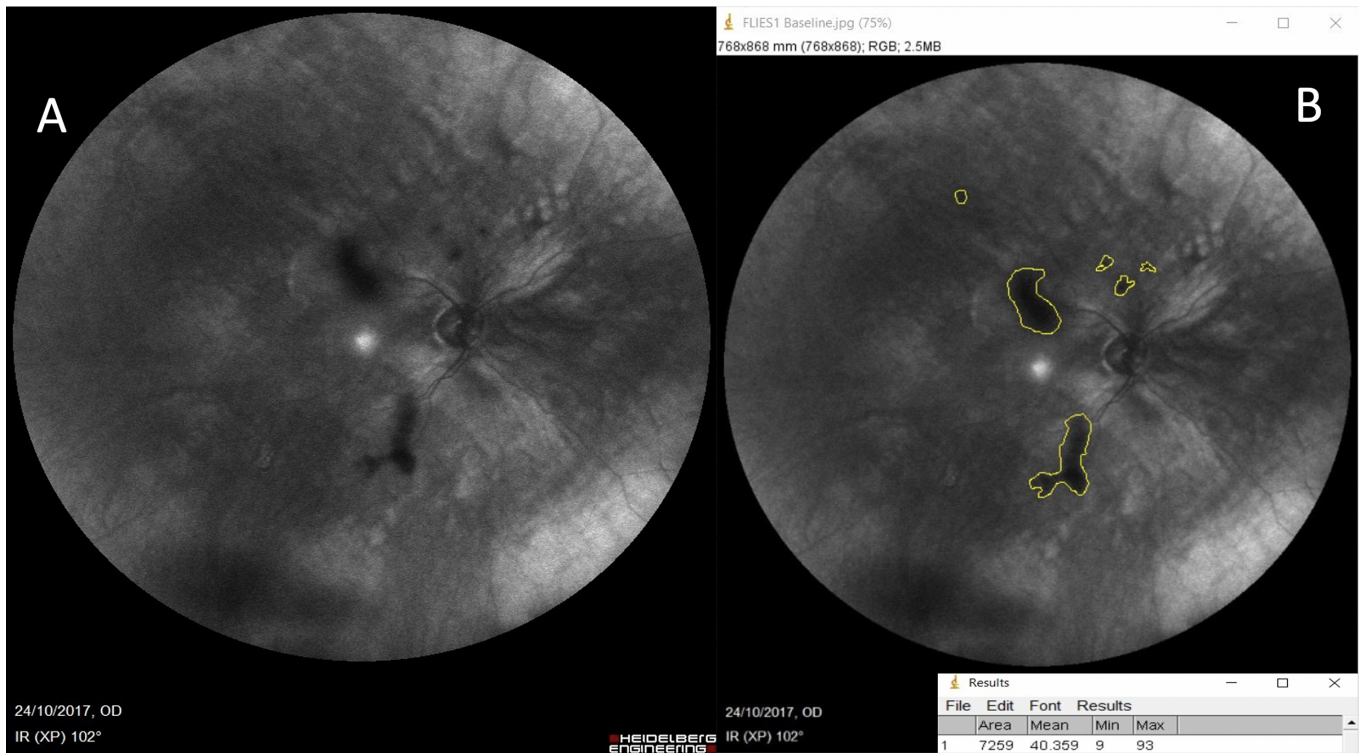
None	Little	Moderate	Much	Very Much
------	--------	----------	------	-----------

At baseline, the intent was to assess the effect of floaters on the patient’s daily life in the week before the study. The question was posed again at the final visit to assess the effect of floaters on the patients’ daily life in the week before the visit. Patients’ responses were reported as simple frequency distributions.

**Vitreous Opacity Area Quantification**

A 30-second, 102° field, cross-polarized infrared reflectance movie of the vitreous was recorded from the study eye using the ultra-widefield angiography module of the Spectralis HRA + optical coherence tomography Multicolor (Heidelberg Engineering GmbH, Heidelberg, Germany). In recording the video, patients were instructed to gaze in the upward, downward, rightward, and leftward directions, and the eye returned back to the internal fixation target of the device after each gaze. This practice allowed for the vitreous opacities to be sufficiently mobile to capture all the potential sizes of the opacities. After the video was acquired, five still, 768 × 868-pixel images were obtained from the video using the Heidelberg Eye Explorer software (Heyex; version 1.10.4.0) and the acquisitions were made when the eye was fixated on the internal target after each of the eye movements. The images were then imported into ImageJ (version 1.53f, National Institute of Health, Bethesda, MD) and





**Figure 2.** Vitreous opacity area quantification using ultra-wide field confocal scanning laser ophthalmoscopy and image J software. Original image imported into imageJ (A). Vitreous opacity area analysis and results (B).

were converted into 8-bit type files, as described by Sun et al.<sup>34</sup> The image scale was set at 1 pixel/mm. Vitreous opacity outlines were manually traced using the ‘freehand selection’ tool. For precise tracing of opacity outlines, the ‘magnifying glass’ tool was used to enlarge the entire image before tracing. After the tracing was completed, the ‘measure’ tool was selected from the ‘analyze’ menu and the software automatically generated the vitreous opacity area (Fig. 2). The results from the five still images were averaged to obtain the vitreous opacity area (in millimeters squared) and have been reported in centimeters squared. A single investigator (E.A.), who was masked to the patients’ allocated groups, conducted all the image analyses. To assess the reliability of this methodology, some patients were randomly imaged twice at either the baseline visit or the final visit under the same testing conditions.

### Visual Function Assessment

BCVA was measured with a computerized LogMAR Early Treatment Diabetic Retinopathy Study test chart (Test Chart 2000 Xpert; Thomson Software Solutions, Hatfield, UK).<sup>35,36</sup> Letter contrast sensitivity was measured at five different spatial frequencies (1.5, 3.0, 7.5, 12.0, and 18.95 cycles per degree) using a computerized Early Treatment

Diabetic Retinopathy Study test chart (Test Chart 2000 PRO).<sup>35–38</sup> Both tests employ Sloan optotypes, displayed at 4 m, to assess visual performance. Functional contrast sensitivity was assessed using the Acuity-plus test from the Advanced Vision and Optometric Test (<https://www.city.ac.uk/avot>).<sup>39,40</sup> This test displays positive and negative polarity Landolt ring optotypes (with gap sizes of 3 min arc or approximately 10 cycles per degree) at 3 m to assess functional contrast sensitivity. Cone and rod sensitivities were measured using the *Flicker-Plus* test (Advanced Vision and Optometric Test system), which displays, at 1 m from the observer, an equiluminant flickering disc modulating sinusoidally at 15 Hz to assess temporal contrast thresholds at the fovea.<sup>41</sup> These methods have been discussed comprehensively elsewhere.<sup>35–42</sup>

Retinal thickness was measured, and PVD was diagnosed, using the Spectralis HRA + optical coherence tomography Multicolor (Heidelberg Engineering GmbH). The 20° × 15° raster scans, consisting of 37 high-resolution line scans, were taken and each scan was separately analyzed by the Spectralis optical coherence tomography retinal thickness algorithm to generate retinal thickness values in micrometers.<sup>43</sup> When sufficient vitreous was identified on the B-scan

to enable PVD assessment, infrared fundus + optical coherence tomography horizontal line scans of the macula were obtained using the 19-line raster scan protocol and a  $20^\circ \times 20^\circ$  scan angle of the macula. The optic disc protocol was also used to obtain a circumferential papillary scan of the optic nerve head. A single vitreoretinal surgeon (E.N.) then assessed and graded all cases into PVD and no PVD, based on the observation of a Weiss ring upon indirect ophthalmoscopic examination and/or a complete separation of the posterior vitreous cortex from the inner limiting membrane along the horizontal macula area on the macula scan and/or from the optic disc on the peripapillary disc scan.

### Montreal Cognitive Assessment

The Montreal Cognitive Assessment test was performed at baseline, as described elsewhere, to assess whether the study patients were mentally capable of responding appropriately to the study questions.<sup>44</sup> Our decision to perform this test was informed by a recent case report describing self-inflicted ocular injuries in a patient with dementia as a result of an altered perception of floaters.<sup>45</sup> A score of 26 and beyond was considered normal and hence, adequate cognitive ability to complete the rest of the study.

### Outcomes

The change in visual discomfort after 6 months of supplementation, assessed with the Floater Disturbance Questionnaire, represented the primary outcome measure (POM). Secondary outcomes were change in quantitative vitreous opacity areas, BCVA, letter contrast sensitivity, and functional contrast sensitivity.

### Statistical Analyses

Based on a POM variable with 3-point scale outcome, a large effect size according to Cohen's definition, and a two-tailed test at the 5% level of significance, we estimated that 26 patients would be required in each interventional arm to attain a power of 80% for the comparison of the two groups.<sup>46</sup> Allowing for a maximum primary end point attrition rate of 14%, 30 patients per intervention group was considered appropriate for this study.

The statistical package IBM SPSS Statistics version 25, Sigma Plot 8, and Microsoft Excel 2016 for Windows were used for all the statistical analyses. Means  $\pm$  standard deviations are presented in the text and tables. Only patients ( $n = 56$ ) who completed the study were included in the analysis in accordance with the FLIES protocol. Between-group differences

in baseline outcome variables were analyzed using independent samples  $t$ -tests for quantitative variables or chi-squared tests for categorical variables as appropriate. Paired samples  $t$ -tests were used to analyze questionnaire outcomes, objective vitreous opacity areas, and visual function measures in each group for change after supplementation. The test-retest reliability of the vitreous opacity area quantification methodology was assessed by computing intraclass correlation coefficient (ICC) estimates and their 95% confident intervals based on a mean rating ( $k = 2$ ), absolute agreement, two-way mixed effects model. An ICC of 0.90 was considered excellent for this methodology. The 5% level of significance was used throughout the analyses.

## Results

### Baseline

Table 1 presents the baseline demographic, visual function, questionnaire characteristics, and vitreous opacity areas for the two groups. The two study groups were comparable for all variables at baseline ( $P > 0.05$  for all).

### POM: Questionnaire Outcomes

Table 2 and Figure 3 present the subjective visual discomfort for the two intervention groups at the baseline and final visits. Table 2 also presents the effect of floaters on daily life for the two intervention groups at the baseline and final visits. Patient responses are presented as summary scores and as frequency distributions.

### Change in Visual Discomfort

*Active Group.* The active group reported less discomfort from floaters at the final visit compared with baseline ( $P < 0.001$ ). At baseline, 1 patient (3.3%) reported a stable condition, 20 patients (66.7%) reported moderate discomfort, and 9 patients (30%) reported persistent discomfort (Table 2; Supplementary Fig. S1A). After supplementation, 11 patients (36.7%) reported a stable condition, 17 patients (57.6%) reported moderate discomfort, and 2 patients (6.67%) reported persistent discomfort. In effect, within the active group, the report of stable condition increased by 33.3%, moderate disturbance decreased by 10%, and persistent disturbance decreased by 23.3%. That is to say, the desired therapeutic effect was achieved in 66.6% of patients within the active group after the intervention.

**Table 1.** Baseline Demographic, Visual Function, Vitreous Opacity Area, and Questionnaire Characteristics of the Placebo and Active Groups

	Placebo ( <i>n</i> = 26)	Active ( <i>n</i> = 30)	Sig.
Age (years)	56.73 ± 14.60	56.67 ± 11.16	0.985
Male sex, <i>n</i> (%)	13 (50)	12 (40)	0.453
Smoking habits, <i>n</i> (%)			0.775
Never smoked	14 (53.85)	15 (50)	
Ex-smoker	11 (42.31)	12 (40)	
Current smoker	1 (3.84)	3 (10)	
Body mass index (kg/m <sup>2</sup> )	27.94 ± 5.03	27.81 ± 4.06	0.919
Montreal Cognitive Assessment score	26.15 ± 2.59	26.70 ± 2.44	0.420
Refractive error status, <i>n</i> (%)			0.953
Myopia	9 (34.62)	11 (36.67)	
Emmetropia	10 (38.46)	12 (40)	
Hyperopia	7 (26.92)	7 (23.33)	
Laterality of floaters, <i>n</i> (%)			0.414
Unilateral	12 (46.15)	10 (33.33)	
Bilateral	14 (53.85)	20 (66.67)	
PVD status, <i>n</i> (%)			0.180
No PVD	10 (38.46)	17 (56.67)	
PVD	16 (61.54)	13 (43.33)	
Visual function			
BCVA, VAR			
Study eye	100.77 ± 9.02	103.00 ± 7.83	0.326
Fellow eye	100.96 ± 9.28	101.03 ± 8.80	0.976
Letter CS, logCS			
1.5 cpd	1.90 ± 0.18	1.96 ± 0.20	0.273
3 cpd	1.87 ± 0.18	1.94 ± 0.19	0.164
7.5 cpd	1.59 ± 0.27	1.66 ± 0.28	0.346
12 cpd	1.27 ± 0.39	1.38 ± 0.36	0.265
18.95 cpd	0.94 ± 0.49	1.07 ± 0.33	0.271
Photopic functional contrast sensitivity, logCS			
Positive	0.75 ± 0.25	0.70 ± 0.32	0.565
Negative	0.76 ± 0.30	0.76 ± 0.33	0.962
Rods sensitivity (%)	8.08 ± 3.26	7.75 ± 3.11	0.707
Cones sensitivity (%)	5.86 ± 2.97	4.84 ± 1.88	0.149
Mean foveal thickness (μm)			
Right eye	285.04 ± 19.94	285.48 ± 21.60	0.940
Left eye	284.40 ± 18.20	286.03 ± 20.56	0.760
Subjective Questionnaire			
Change in discomfort since onset	3.69 ± 1.54	3.90 ± 1.56	0.797
Effect of floaters on daily life	1.08 ± 0.85	1.37 ± 1.27	0.328
Vitreous opacity area (cm <sup>2</sup> )*	125.55 ± 103.20	121.31 ± 90.96	0.882

Data displayed are mean ± standard deviation for interval data and percentages for categorical data. BCVA was measured with the Test Chart Xpert (Thomson Software Solutions), BCVA was reported in visual acuity rating (VAR). Letter contrast sensitivity measured with the MiQ Contrast 256 test and recorded as log (contrast sensitivity). Photopic functional contrast sensitivity were measured with the Acuity-plus test from the Advanced Vision and Optometric Test (AVOT). Flicker sensitivity (for rods and cones sensitivities) measured with the *Flicker*-plus test from the AVOT Suite and recorded as flicker threshold (%). Foveal thickness measured with Spectralis HRA + optical coherence tomography multicolor and recorded as micrometers. Vitreous opacity area measured with the Spectralis HRA + optical coherence tomography multicolor and ImageJ, and recorded as cm<sup>2</sup>. cpd, cycles per degree; CS, contrast sensitivity; Sig., the statistical difference between the two groups.

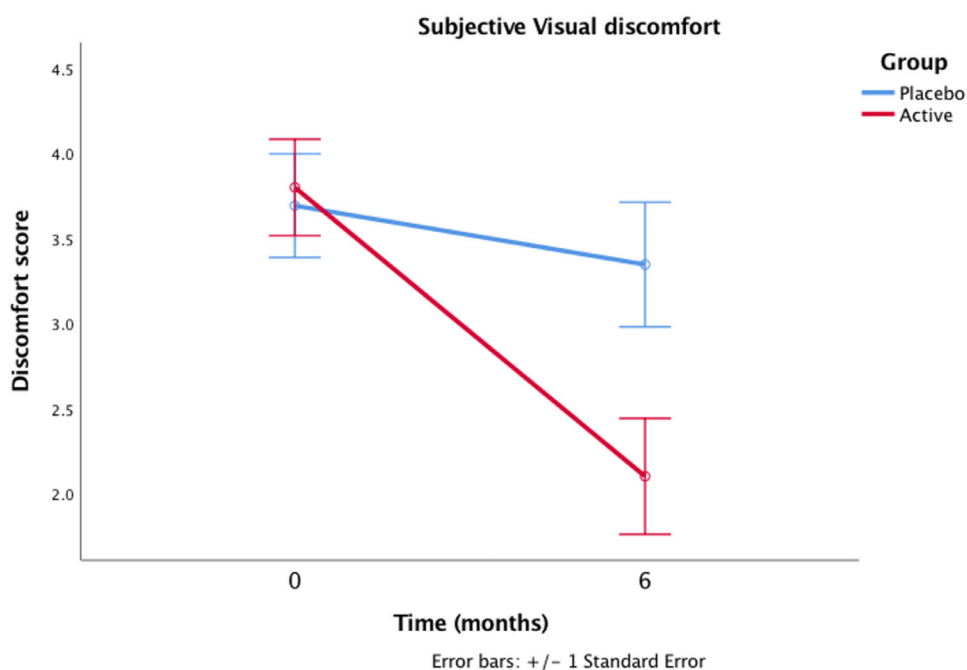
\* *n* = 21 and *n* = 26 for the placebo and active groups, respectively.

**Table 2.** Subjective Questionnaire Outcomes for the Two Intervention Groups

Questionnaire Items	Placebo Group (n = 26)			Active Group (n = 30)		
	Baseline	Final	P Value	Baseline	Final	P Value
<b>Visual discomfort</b>						
Stable condition	1 (3.85)	4 (15.38)	0.416	1 (3.33)	11 (36.67)	<0.001*
Moderate discomfort	19 (73.07)	15 (57.69)		20 (66.67)	17 (56.67)	
Persistent discomfort	6 (23.07)	7 (26.92)		9 (30)	2 (6.67)	
Mean score	3.69 ± 1.54	3.35 ± 1.96		3.90 ± 1.56	2.10 ± 1.79	
<b>Effect on daily life</b>						
None	7 (26.92)	10 (38.46)	0.678	9 (30)	15 (50)	0.002*
Little	11 (42.31)	9 (34.62)		9 (30)	10 (33.33)	
Moderate	7 (26.92)	5 (19.23)		7 (23.33)	4 (13.33)	
Much	1 (3.85)	1 (3.85)		2 (6.67)	1 (3.33)	
Very much	0	1 (3.85)		3 (10)	0	
Mean score	1.08 ± 0.85	1.00 ± 1.06		1.37 ± 1.27	0.73 ± 0.94	

P is the difference between baseline and final visit (paired sample t test).

\*Statistical significance between baseline and final visit.



**Figure 3.** Subjective visual discomfort at baseline and final visit for the active and placebo groups. Active group (n = 30), 125 mg/d l-lysine, 40 mg/d vitamin C, 26.3 mg/d *V. vinifera* extract, 5 mg/d zinc, and 100 mg of *C. aurantium*; placebo group (n = 26), microcrystalline cellulose.

**Placebo Group.** The visual discomfort from floaters reported by the placebo group did not differ significantly at final visit when compared with their baseline reports (P = 0.416). At baseline, 1 patient (3.8%) reported a stable condition, 19 patients (73.1%) reported moderate discomfort, and 6 patients (23.1%) reported that their floaters had been consistently bothersome (Table 2; Supplementary Fig. S1B). After supplementation, 4 patients

(15.4%) reported a stable condition, 15 (57.7%) had moderate discomfort, and 7 patients (26.9%) reported persistent discomfort. In effect, within the placebo group, report of stable condition increased by 11.53%, moderate disturbance decreased by 15.38%, and persistent disturbance increased by 3.85%. In other words, 26.9% of patients within the placebo group reported a positive placebo effect.



### Change in Effect of Floaters on Daily Life

**Active Group.** The active group reported a lesser effect of floaters on their daily life at the final visit compared with baseline ( $1.37 \pm 1.27$  and  $0.73 \pm 0.94$  for baseline and final visits, respectively;  $P = 0.002$ ). At baseline, nine patients (30%) had no effect, nine patients (30%) had little effect, seven patients (23.3%) had moderate effect, two patients (6.7%) had much effect, and three patients (10%) had very much effect, of their floaters on their daily life (Table 2; Supplementary Fig. S2A). After supplementation, 15 patients (50%) reported no effect, 10 patients (33.3%) reported little effect, 4 patients (13.3%) reported moderate effect, and 1 patient (3.3%) reported much effect, of their floaters on their daily life and this improvement was statistically significant.

**Placebo Group.** The subjective reports by the placebo group did not differ significantly at the final visit when compared with their baseline reports ( $1.08 \pm 0.85$  and  $1.00 \pm 1.06$  for baseline and final visits, respectively;  $P = 0.678$ ). At baseline, 7 patients (26.9%) reported no effect, 11 patients (42.3%) reported little effect, 7 patients (26.9%) reported moderate effect, and 1 patient (3.8%) reported much effect, of their floaters on their daily life (Table 2; Supplementary Fig. S2B). After supplementation, 10 patients (38.5%) reported

no effect, nine patients (34.6%) reported little effect, five patients (19.2%) reported moderate effect, one patient (3.8%) reported much effect, and one patient (3.8%) reported very much effect, of their floaters on their daily life.

### Change in Vitreous Opacity Areas Over Time

Table 3 and Figure 4 show the change in vitreous opacity areas of the two groups before and after supplementation. There was a significant decrease in vitreous opacity areas after supplementation in the active group ( $P = 0.002$ ; Figs. 4 and 5). There was an increase in vitreous opacity areas in the placebo group after 6 months of supplementation, but the increase was not significant ( $P = 0.081$ ; Figs. 4 and 6). There was a decrease in vitreous opacity areas in 20 out of 26 patients (76.9%) in the active group compared with 6 out of 21 patients (28.6%) in the placebo group.

The test–retest reliability was conducted using 10 eyes of 10 patients (5 males, 5 females) selected at random at baseline and 20 eyes of 17 different patients (4 males, 13 females) selected at random at the final visit. The test revealed an ICC of 0.998 (95% CI: 0.991 – 0.999;  $P < 0.001$ ) at baseline and 0.998 (95% CI: 0.994 – 0.999;  $P < 0.001$ ) at final visit, indicating excellent reliability of the methodology.

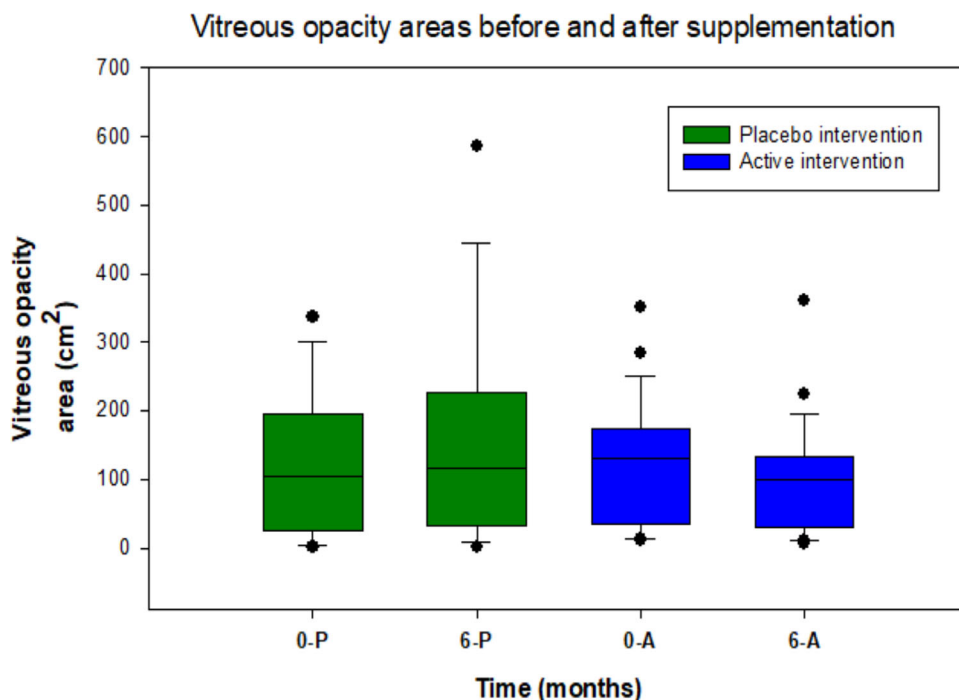
**Table 3.** Visual Function and Vitreous Opacity Area Outcomes From Baseline to Final Study Visit for the Two Study Groups

Variables	Placebo Group (n = 26)			Active Group (n = 30)		
	Baseline	6 Months	Sig.	Baseline	6 Months	Sig.
BCVA	100.77 ± 9.02	103.08 ± 6.01	0.185	103.00 ± 7.83	102.33 ± 7.51	0.502
Letter CS (logCS)						
Test Chart 2000 Pro						
1.5 cpd	1.90 ± 0.18	1.93 ± 0.14	0.354	1.96 ± 0.20	1.95 ± 0.19	0.749
3 cpd	1.87 ± 0.18	1.89 ± 0.17	0.465	1.94 ± 0.19	1.98 ± 0.22	0.109
7.5 cpd	1.59 ± 0.27	1.62 ± 0.23	0.353	1.66 ± 0.28	1.65 ± 0.34	0.746
12 cpd	1.27 ± 0.39	1.39 ± 0.29	0.104	1.38 ± 0.36	1.42 ± 0.40	0.510
18.95 cpd	0.94 ± 0.49	1.02 ± 0.38	0.276	1.07 ± 0.33	1.12 ± 0.33	0.281
MiQ 256	1.67 ± 0.25	1.72 ± 0.25	0.508	1.65 ± 0.29	1.75 ± 0.30	0.059
Photopic functional contrast sensitivity (logCS)						
Positive	0.75 ± 0.25	0.74 ± 0.27	0.883	0.70 ± 0.32	0.76 ± 0.32	0.047*
Negative	0.76 ± 0.30	0.81 ± 0.30	0.223	0.76 ± 0.32	0.79 ± 0.34	0.274
Rod sensitivity (%)	8.08 ± 3.26	7.76 ± 2.85	0.374	7.75 ± 3.11	7.26 ± 2.74	0.110
Cone sensitivity (%)	5.86 ± 2.97	5.37 ± 3.18	0.159	4.84 ± 1.88	4.84 ± 1.85	0.996
Vitreous opacity area (cm <sup>2</sup> ) <sup>†</sup>	125.55 ± 103.20	155.07 ± 156.87	0.081	121.31 ± 90.96	99.78 ± 79.87	<0.001*

BCVA was measured with the Test Chart Xpert (Thomson Software Solutions). Letter contrast sensitivity (CS) measured with the Test Chart Pro 2000 and the MiQ Contrast 256 test; Photopic functional contrast sensitivity (CS) were measured with the Acuity-plus test from the Advanced Vision and Optometric Test (AVOT); Sig., the statistical difference between baseline and 6 months (paired samples *t*-test).

\* Statistically significant difference at the 0.05 level between baseline and 6 months.

<sup>†</sup> *n* = 21 and *n* = 26 for the placebo and active groups, respectively.



**Figure 4.** Boxplots illustrating the vitreous opacity areas at baseline and final visit for the active and placebo groups. 0-P, baseline placebo group; 6-P, 6 months placebo group; 0-A, baseline active group; 6-A, 6 months active group.

## Change in Visual Function Over Time

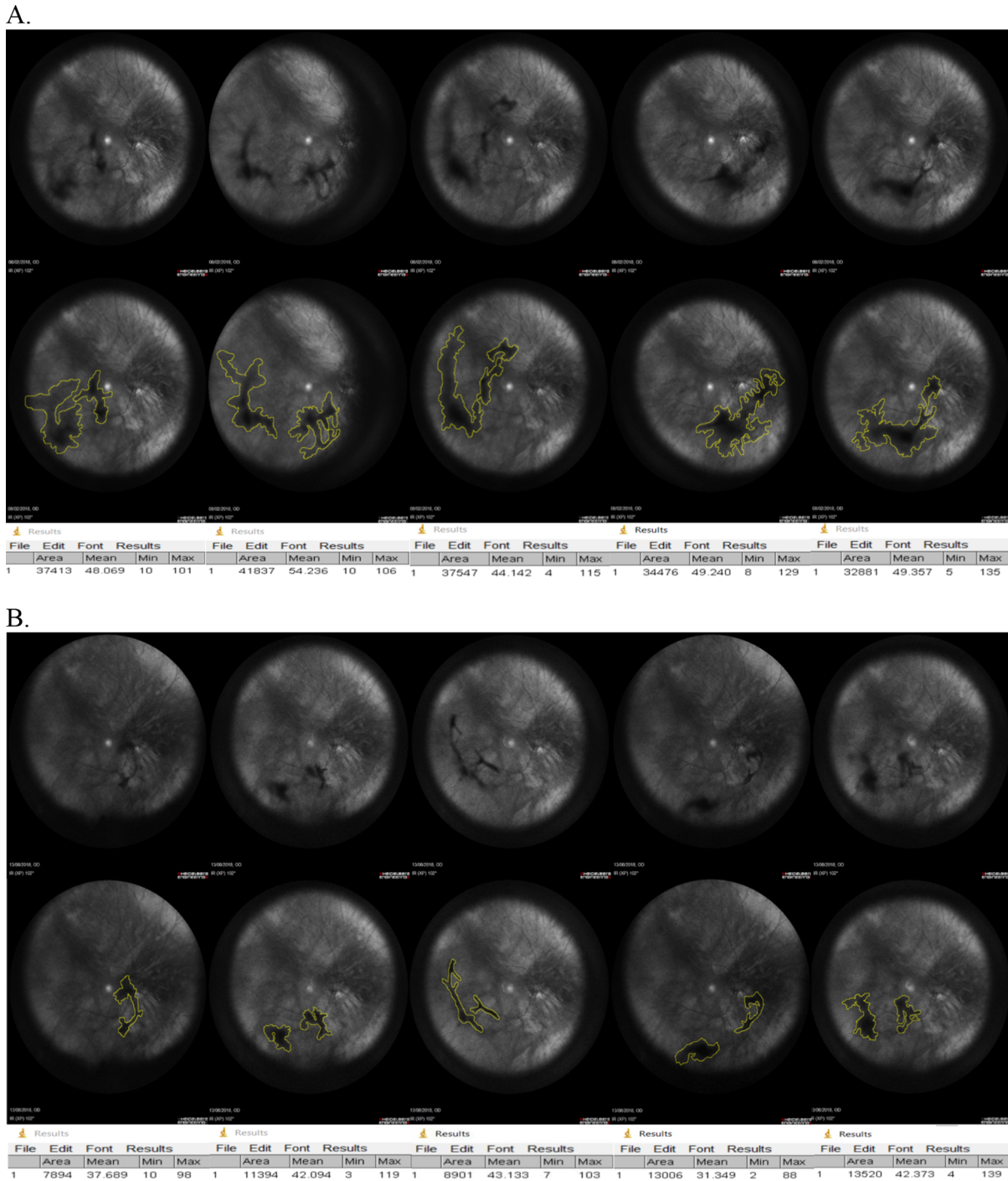
Table 3 displays the visual function outcomes of the two groups after supplementation. There was no significant difference in BCVA, letter contrast sensitivity, or photopic functional contrast sensitivity with negative polarity in either of the study groups ( $P > 0.05$  for all). The active group reported statistically significant improvement in photopic functional contrast sensitivity with positive polarity after supplementation ( $P = 0.047$ ).

## Discussion

This study is the first to assess the impact of targeted nutritional supplementation on patient suffering associated with vitreous floaters, in the context of a randomized, double-blind, placebo-controlled clinical trial. Here, we report a significant decrease in subjective visual discomfort from floaters, a significant decrease in vitreous opacity area, and a significant improvement in contrast sensitivity after 6 months of supplementation with the active formulation. The observed benefit in the active group confirms our initial hypothesis that dietary intake of a formulation of antioxidative and antiglycation micronutrients could avail relevant micronutrients capable of mitigating the mechanisms underly-

ing vitreous degeneration, thereby decreasing the visual discomfort associated with vitreous floaters.

Oxidative stress (secondary to increased intravitreal free radicals), accumulation of nonenzymatic glycation end products, and decreased vitreous antioxidant capacity underpin vitreous degeneration, typified by vitreous collagen aggregation and glycation as well as hyaluronan depolymerization.<sup>4,47,48</sup> The micronutrients within the active supplement exert specific antioxidative and antiglycation activities against the processes described elsewhere in this article and provide a potentially low-risk and feasible option for managing vitreous degeneration. L-Lysine prevents collagen glycation and also acts as a chemical chaperone.<sup>28,49</sup> Vitamin C guards against intraocular oxidative stress by consuming oxygen released at the vitreoretinal interface in an ascorbate-dependent fashion.<sup>50</sup> Zinc acts as a stimulus for the synthesis of metallothionein, a metal-binding protein which protects tissues from glycoxidation (a mechanism that leads to vitreous degeneration).<sup>51,52</sup> Zinc has also been shown to possess antioxidative and antiglycation properties, and zinc supplementation could inhibit formation of advanced glycation end-products and advanced glycation end-product-induced oxidative stress.<sup>53</sup> Proanthocyanidin in *V. vinifera* exerts an inhibitory effect on protein glycation. Hesperidin prevents oxidative stress by inhibiting the formation and accumulation of cross-linking

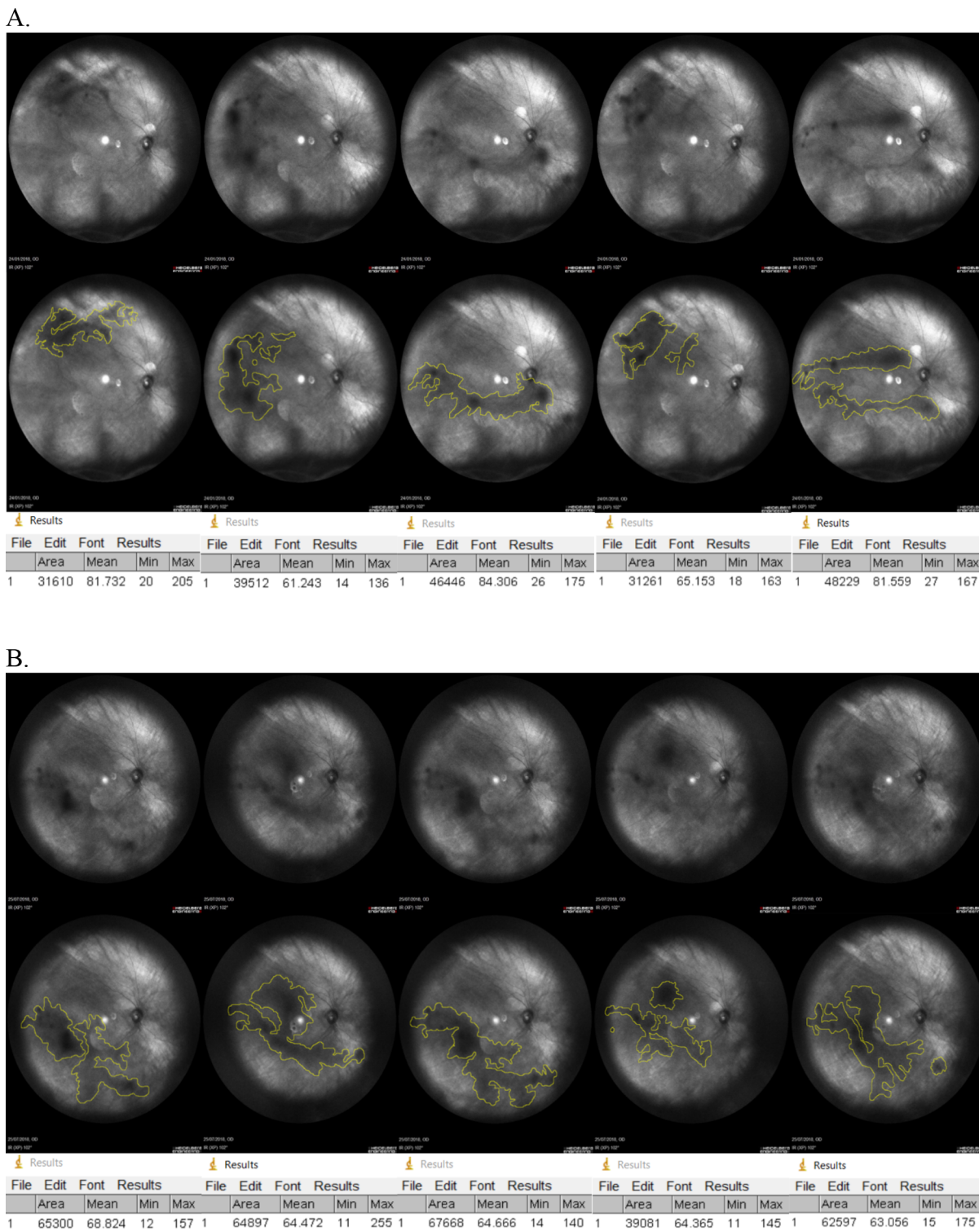


**Figure 5.** Vitreous opacity quantification for a patient within the active group who reported persistent discomfort at baseline and moderate disturbance at the final visit, showing an average vitreous opacity area of 368.31 cm<sup>2</sup> at baseline (A) and 109.43 cm<sup>2</sup> at the final visit (B).

advanced glycation end products in collagens and tissues.<sup>29,31</sup>

We have previously postulated that attaining therapeutic, intravitreal levels of these exogenous micronutrients may require a repeated, long-term administration of the micronutrients.<sup>4</sup> In addition, we have comprehensively reviewed elsewhere the concentra-

tions and potential mode of delivery of exogenous micronutrients into vitreous. In brief, the concentrations of L-lysine, zinc, and vitamin C previously detected in the adult vitreous are 115 μM, 1.95 μM/L, and 2 mM/L, respectively.<sup>4,32,54</sup> The vitreous gel receives its supply of Vitamin C from the plasma by an active transport from the ciliary process of the ciliary



**Figure 6.** Vitreous opacity quantification for a patient within the placebo group who reported persistent disturbance at both baseline and final visits, showing an average vitreous area of 394.12 cm<sup>2</sup> at baseline (**A**) and 599.09 cm<sup>2</sup> at the final visit (**B**).

body (Socci R, et al. IOVS. 1987;4:ARVO Abstract 74). Like all soluble intravitreal proteins or amino acids, L-lysine may be sourced via local secretion, filtration from the blood, or diffusion from the surround-

ing tissues and vasculature.<sup>55</sup> Although proanthocyanidins generally enter the systemic circulation via passive diffusion, it is only *3,4-dihydroxyphenylacetic acid*, a potent antioxidant as well as a metabolite of



proanthocyanidin, that has been detected within the human vitreous.<sup>56–58</sup>

Because limited literature exists on the delivery channels for exogenous micronutrients into vitreous, we have previously conjectured based on evidence from fluorometry studies and post mortem toxicological analyses that the transfer of molecules from the systemic circulation into the human vitreous may be mediated by diffusion, hydrostatic and osmotic pressure gradients, convection, and active transport, through the blood–aqueous and blood–retina barriers (Socci R, et al. IOVS. 1987;4:ARVO Abstract 74).<sup>4,59,60</sup> Because the micronutrients as described elsewhere in this article have been detected previously in the human vitreous, we can theorize that these nutrients use the pathways described to accumulate in vitreous, although the specific delivery channels have not been isolated for most of these nutrients.<sup>4</sup> Our findings confirm our prior postulation and suggest that supplementation with the formulation of antioxidative and antiglycation micronutrients for 6 months delivers therapeutic doses of intravitreal targeted micronutrients, whose collective action against vitreous degenerative mechanisms result in an improvement in quality of life of patients in the active group. What is not clear from the present study is whether the vitreous degenerative process will commence once the intervention has been halted and accumulated intravitreal micronutrients have been used up. Future studies are warranted to estimate the concentrations of these micronutrients within vitreous after supplementation. Further, future studies on targeted nutrition for optimizing vitreous may be also concerned with giving higher doses of the individual micronutrients (not exceeding the upper reference levels of the micronutrients) to ensure higher intravitreal levels within the therapeutic range.

In the present study, the active and placebo groups were comparable in their visual discomfort scores at baseline ( $P = 0.797$ ). However, it is worth mentioning that there was a slightly high, albeit not statistically significant, difference in the PVD rate (61.5% vs 43.3% in the placebo and active groups, respectively) between the two groups at baseline. Given that the densest and most central floaters could have resulted from the detached posterior hyaloid face as part of a PVD, a large (significant) difference in PVD rate between the groups could have potentially influenced our POM, especially when the two groups were compared.<sup>61,62</sup> As a consequence, a similar representation of such cases in both groups would have been the ideal scenario to allow for a comparison between the two groups. Interestingly, the two study groups had similar objective vitreous opacity area measurements at the onset of

the study, implying that the groups were comparable. In addition, the main findings and conclusions herein presented were based on the paired group comparisons for each study group, in which a group's own outcomes at baseline and final visits were compared for change over time, and not on the between-group comparisons.

After supplementation, the active group reported a significantly lesser visual discomfort score compared with the placebo group ( $P = 0.016$ ). Our results suggest that the active formulation is an effective intervention that improves the vision-related quality of life of patients with floaters. Given that patients with floaters are typically observed for 6 months before any treatment is considered, it is our view that supplementation with this clinically tested formulation of antioxidative and antiglycation micronutrients could be considered rather than proffering watchful waiting.

There was a significant decrease in vitreous opacity areas after supplementation in the active group. The findings from this methodology confirm the subjective report of improvement within the active group. The use of ImageJ software to quantify vitreous opacities was first described by Sun et al, who computed floater shadow areas from 30° or 55°, 768 × 768 pixel infrared fundus images for patients who underwent laser vitreolysis for symptomatic floaters. What they found was a significant decrease in floater shadow areas after the procedure. Our methodology of ultra-widefield imaging (102° field) of vitreous described in this study is an improvement on their approach which involved imaging a 30° or 55° field of the retina. In addition, our ICC with 95% confidence interval indicated excellent level of reliability of our methodology, suggesting that the data herein presented are reliable estimates of the vitreous opacity areas of patients at the two time points.

With respect to visual function, the results from the current trial are impressive. Here, we report an improvement of 0.06 log units (equivalent to two optotypes on an Early Treatment Diabetic Retinopathy Study logMAR test chart at 10 cycles per degree), on average, in the active group for photopic functional contrast sensitivity with positive polarity stimulus after supplementation ( $P = 0.047$ ). Degenerated vitreous causes intraocular light scattering and degrade both photopic and mesopic contrast sensitivity.<sup>10,20,63</sup> The functional contrast sensitivity test used in the present study uses a stimulus reach in high spatial frequencies, which are significantly influenced by optical factors including forward light scatter. Hence, improvement in photopic functional contrast sensitivity, with an associated decrease in subjective visual discomfort and objective vitreous opacity areas, suggests a decrease

in forward light scatter from vitreous opacities within the active group after supplementation with the active formulation. Further, there was no significant change in rods and cones sensitivity, implying that the improvement in contrast sensitivity observed is not as a result of an improvement in retinal function, but rather is from an improved vitreous health.

A limitation of this study is that no vitreous biopsies were taken to measure the intravitreal concentrations of the micronutrients after supplementation. The present study was designed to assess the efficacy of a noninvasive, low-risk therapy for floaters. Acquiring vitreous samples via invasive procedures such as vitrectomy or vitreous aspiration needle tap would have violated the protocol of this study.<sup>64</sup> This study, however, provides initial data that pave way for future studies designed to estimate the concentrations of the targeted micronutrients (as well as total antioxidant capacity) within vitreous samples from supplemented patients as well as nonsupplemented controls.

Another limitation is that the questionnaire used in this study was developed specifically for the trial and therefore has not been used previously or validated by other researchers. Therefore, this factor may increase the tendency to introduce noise into the measurement and decrease sensitivity to change and correlations with other variables, given that it is a nonvalidated patient-reported outcome measure.<sup>65</sup> However, these errors are frequent when a composite score is generated based on the individual scores of questions within a nonvalidated patient-reported outcome measure. Our approach of scoring the individual questionnaire items were constructed to limit noise and provide reliable outcomes regarding patients' visual discomfort.

In addition, a single masked investigator conducted all the image analysis for the objective vitreous opacity areas quantification. Although the investigator manually traced the outlines of the opacity, the actual opacity areas were quantified automatically by the software. Further, all the analyzed images were inspected by the entire study team to ensure that all opacities within images had been correctly outlined to ensure accuracy in the methodology. We did not attempt to distinguish between central and peripheral floaters with our objective methodology. Central floaters may cause more symptoms, so future studies comparing central and peripheral floaters would be useful.

Visual inspection of the raw data from the trial is clear and impressive, indicating a positive impact of supplementation with the active ingredient for patient suffering and visual function. Further, the data presented in this report have provided a proof of concept that targeted nutritional intervention is a

promising new approach for managing vitreous degeneration that requires further exploration. What remains to be explored is the duration and dosing that will elicit the highest therapeutic response with little to no systemic effects.

## Conclusions

This study is the first to investigate the impact of targeted nutritional intervention via supplementation for patients suffering from vitreous floaters in a double-blind, placebo-controlled fashion. The findings of this clinical trial indicate improvements in vision-related quality of life and visual function of patients suffering from vitreous floaters after supplementation with a formulation of antioxidative and antiglycation micronutrients. Notably, these improvements were confirmed by the decrease in vitreous opacity areas in the active group. This targeted dietary intervention should be considered to support patients with symptomatic vitreous degeneration.

## Acknowledgments

Funded by Waterford Institute of Technology (WIT) and ebiga-VISION GmbH through a WIT PhD Co-Fund Scholarship (WD\_2017\_43).

There is a royalty agreement in place between ebiga-VISION GmbH and WIT based on the intellectual property and the patent submitted as part of the study. EA and JMN are listed as inventors on the patent application which is pending, and cannot disclose any conflict of interest at this point in time.

Disclosure: **E. Ankamah**, None; **M. Green-Gomez**, None; **W. Roche**, None; **E. Ng**, None; **U. Welge-Lüssen**, None; **T. Kaercher**, None; **J.M. Nolan**, None

## References

1. Milston R, Madigan MC, Sebag J. Vitreous floaters: etiology, diagnostics, and management. *Survey Ophthalmol.* 2016;61:211–227.
2. Harocopos GJ, Shui Y-B, McKinnon M, Holekamp NM, Gordon MO, Beebe DC. Importance of vitreous liquefaction in age-related cataract. *Invest Ophthalmol Vis Sci.* 2004;45:77–85.
3. Vaughan-Thomas A, Gilbert SJ, Duance VC. Elevated levels of proteolytic enzymes in the

- aging human vitreous. *Invest Ophthalmol Vis Sci.* 2000;41:3299–3304.
4. Ankamah E, Sebag J, Ng E, Nolan JM. Vitreous antioxidants, degeneration, and vitreoretinopathy: exploring the links. *Antioxidants.* 2020;9:7.
  5. Napolitano F, Di Iorio V, Di Iorio G, et al. Early posterior vitreous detachment is associated with LAMA5 dominant mutation. *Ophthalmic Genet.* 2019;40:39–42.
  6. Chuo JY, Lee TYY, Hollands H, et al. Risk factors for posterior vitreous detachment: a case-control study. *Am J Ophthalmol.* 2006;142:931–937.
  7. Akiba J. Prevalence of posterior vitreous detachment in high myopia. *Ophthalmology.* 1993;100:1384–1388.
  8. Morita H, Funata M, Tokoro T. A clinical study of the development of posterior vitreous detachment in high myopia. *Retina (Philadelphia, Pa).* 1995;15:117–124.
  9. Lumi X, Hawlina M, Glavač D, et al. Ageing of the vitreous: from acute onset floaters and flashes to retinal detachment. *Ageing Res Rev.* 2015;21:71–77.
  10. Garcia GA, Khoshnevis M, Yee KMP, Nguyen-Cuu J, Nguyen JH, Sebag J. Degradation of contrast sensitivity function following posterior vitreous detachment. *Am J Ophthalmol.* 2016;172:7–12.
  11. Sebag J. Floaters and the quality of life. *Am J Ophthalmol.* 2011;152:3–4.e1.
  12. Cipolletta S, Beccarello A, Galan A. A psychological perspective of eye floaters. *Qual Health Res.* 2012;22:1547–1558.
  13. Zou H, Liu H, Xu X, Zhang X. The impact of persistent visually disabling vitreous floaters on health status utility values. *Qual Life Res.* 2013;22:1507–1514.
  14. Wagle AM, Lim WY, Yap TP, Neelam K, Au Eong KG. Utility values associated with vitreous floaters. *Am J Ophthalmol.* 2011;152:60–65.e61.
  15. Sendrowski DP, Bronstein MA. Current treatment for vitreous floaters. *Optometry.* 2010;81:157–161.
  16. Repetto R, Siggers JH, Stocchino A. Mathematical model of flow in the vitreous humor induced by saccadic eye rotations: effect of geometry. *Biomech Model Mechanobiol.* 2010;9:65–76.
  17. Stocchino A, Repetto R, Siggers JH. Mixing processes in the vitreous chamber induced by eye rotations. *Phys Med Biol.* 2009;55:453.
  18. Sebag J, Yee KMP, Wa CA, Huang LC, Sadun AA. Vitrectomy for floaters: prospective efficacy analyses and retrospective safety profile. *Retina.* 2014;34:1062–1068.
  19. de Nie KF, Crama N, Tilanus MAD, Klevering BJ, Boon CJF. Pars plana vitrectomy for disturbing primary vitreous floaters: clinical outcome and patient satisfaction. *Graefe Arch Clin Exp Ophthalmol.* 2013;251:1373–1382.
  20. Sebag J, Yee KMP, Nguyen JH, Nguyen-Cuu J. Long-term safety and efficacy of limited vitrectomy for vision degrading vitreopathy resulting from vitreous floaters. *Ophthalmol Retina.* 2018;2:881–887.
  21. Mossa F, Delaney YM, Rosen PH, Rahman R. Floaterectomy: combined phacoemulsification and deep anterior vitrectomy. *J Cataract Refract Surg.* 2002;28:589–592.
  22. Sa A, Elawadi AI. Liquefaction of the vitreous humor floaters is a risk factor for lens opacity and retinal dysfunction. *Journal of American Science.* 2011;7:927–936.
  23. Wilkinson CP. Safety of vitrectomy for floaters—how safe is safe? *Am J Ophthalmol.* 2011;151:919–920.e911.
  24. Hahn P, Schneider EW, Tabandeh H, Wong RW, Emerson GG. Reported complications following laser vitreolysis. *JAMA Ophthalmol.* 2017;135:973–976.
  25. Abdelkawi SA, Abdel-Salam AM, Ghoniem DF, Ghaly SK. Vitreous humor rheology after Nd:YAG laser photo disruption. *Cell Biochem Biophys.* 2014;68:267–274.
  26. Cowan LA, Khine KT, Chopra V, Fazio DT, Francis BA. Refractory open-angle glaucoma after neodymium–yttrium–aluminum–garnet laser lysis of vitreous floaters. *Am J Ophthalmol.* 2015;159:138–143.
  27. Koo EH, Haddock LJ, Bhardwaj N, Fortun JA. Cataracts induced by neodymium–yttrium–aluminum–garnet laser lysis of vitreous floaters. *Br J Ophthalmol.* 2017;101:709–711.
  28. Sulochana KN, Ramprasad S, Coral K, et al. Glycation and glycooxidation studies in vitro on isolated human vitreous collagen. *Med Sci Monit.* 2003;9:BR220–BR224.
  29. Urios P, Grigorova-Borsos A-M, Sternberg M. Flavonoids inhibit the formation of the cross-linking AGE pentosidine in collagen incubated with glucose, according to their structure. *Eur J Nutr.* 2007;46:139.
  30. Mosca M, Ambrosone L, Semeraro F, Casamasima D, Vizzarri F, Costagliola C. Ocular tissues and fluids oxidative stress in hares fed on verbascoside supplement. *Int J Food Sci Nutr.* 2014;65:235–240.
  31. Shi X, Liao S, Mi H, et al. Hesperidin prevents retinal and plasma abnormalities in streptozotocin-



- induced diabetic rats. *Molecules*. 2012;17:12868–12881.
32. Honkanen RA, Baruah S, Zimmerman MB, et al. Vitreous amino acid concentrations in patients with glaucoma undergoing vitrectomy. *Arch Ophthalmol*. 2003;121:183–188.
  33. Ishikawa S, Nakazawa M, Ishikawa A, Ishiguro S-I, Tamai M. Alteration of glutamine concentration in the vitreous humor in patients with proliferative vitreoretinopathy. *Curr Eye Res*. 1995;14:191–197.
  34. Sun X, Tian J, Wang J, Zhang J, Wang Y, Yuan G. Nd:YAG laser vitreolysis for symptomatic vitreous floaters: application of infrared fundus photography in assessing the treatment efficacy. *Journal of Ophthalmology*. 2019;2019:8695952.
  35. Akuffo KO, Beatty S, Stack J, et al. Central Retinal Enrichment Supplementation Trials (CREST): design and methodology of the CREST randomized controlled trials. *Ophthalmic Epidemiol*. 2014;21:111–123.
  36. Charalampidou S, Nolan J, Loughman J, et al. Psychophysical impact and optical and morphological characteristics of symptomatic non-advanced cataract. *Eye (Lond)*. 2011;25:1147–1154.
  37. Thayaparan K, Crossland MD, Rubin GS. Clinical assessment of two new contrast sensitivity charts. *Br J Ophthalmol*. 2007;91:749–752.
  38. Loughman J, Nolan JM, Howard AN, Connolly E, Meagher K, Beatty S. The impact of macular pigment augmentation on visual performance using different carotenoid formulations. *Invest Ophthalmol Vis Sci*. 2012;53:7871–7880.
  39. Gillespie-Gallery H, Konstantakopoulou E, Harlow JA, Barbur JL. Capturing age-related changes in functional contrast sensitivity with decreasing light levels in monocular and binocular vision. *Invest Ophthalmol Vis Sci*. 2013;54:6093–6103.
  40. Keuken A, Subramanian A, Barbur JL. Normal upper age-limits for photopic and mesopic visual acuity and functional contrast sensitivity. *Acta Ophthalmol*. 2017;95:s259.
  41. Bi W, Gillespie-Gallery H, Binns A, Barbur JL. Flicker sensitivity in normal aging—monocular tests of retinal function at photopic and mesopic light levels. *Invest Ophthalmol Vis Sci*. 2016;57:387–395.
  42. Smolarek-Kasprzak P, Nolan JM, Beatty S, et al. Measuring visual function using the MultiQuity system: comparison with an established device. *J Ophthalmol*. 2014;2014:1–7.
  43. Menke MN, Dabov S, Knecht P, Sturm V. Reproducibility of retinal thickness measurements in healthy subjects using Spectralis optical coherence tomography. *Am J Ophthalmol*. 2009;147:467–472.
  44. Nasreddine ZS, Phillips NA, Bedirian V, et al. The Montreal Cognitive Assessment, MoCA: a brief screening tool for mild cognitive impairment. *J Am Geriatr Soc*. 2005;53:695–699.
  45. Griffith W, Kane S, Gibran SK. Altered perception of floaters in dementia causing self-inflicted injuries. *Int J Ophthalmol*. 2017;10:1181.
  46. Cohen J. *Statistical power analysis for the behavioral sciences*. 2nd ed. Hillsdale, NJ: Lawrence Erlbaum Associates; 1988.
  47. Deguine V, Menasche M, Ferrari P, Fraisse L, Pouliquen Y, Robert L. Free radical depolymerization of hyaluronan by Maillard reaction products: role in liquefaction of aging vitreous. *Int J Biol Macromol*. 1998;22:17–22.
  48. Deguine V, Labat-Robert J, Ferrari P, Pouliquen Y, Menasche M, Robert L. Aging of the vitreous body. Role of glycation and free radicals. *Pathol Biol (Paris)*. 1997;45:321–330.
  49. Awasthi S, Saraswathi NT. Carbonyl scavenging and chemical chaperon like function of essential amino acids attenuates non-enzymatic glycation of albumin. *RSC Adv*. 2016;6:24557–24564.
  50. Shui Y-B, Holekamp NM, Kramer BC, et al. The gel state of the vitreous and ascorbate-dependent oxygen consumption: relationship to the etiology of nuclear cataracts. *Arch Ophthalmol*. 2009;127:475–482.
  51. Konerirajapuram NS, Coral K, Punitham R, Sharma T, Kasinathan N, Sivaramakrishnan R. Trace elements iron, copper and zinc in vitreous of patients with various vitreoretinal diseases. *Indian J Ophthalmol*. 2004;52:145–148.
  52. Sato M, Kondoh M. Recent studies on metallothionein: protection against toxicity of heavy metals and oxygen free radicals. *Tohoku J Exp Med*. 2002;196:9–22.
  53. Kheirouri S, Alizadeh M, Maleki V. Zinc against advanced glycation end products. *Clin Exp Pharmacol Physiol*. 2018;45:491–498.
  54. Kokavec J, Min SH, Tan MH, et al. Biochemical analysis of the living human vitreous. *Clin Exp Pharmacol Physiol*. 2016;44:597–609.
  55. Wu CW, Sauter JL, Johnson PK, Chen C-D, Olsen TW. Identification and localization of major soluble vitreous proteins in human ocular tissue. *Am J Ophthalmol*. 2004;137:655–661.
  56. Appeldoorn MM, Vincken J-P, Aura A-M, Hollman PCH, Gruppen H. Procyanidin dimers are metabolized by human microbiota with 2-(3, 4-dihydroxyphenyl) acetic acid and



- 5-(3, 4-dihydroxyphenyl)- $\gamma$ -valerolactone as the major metabolites. *J Agric Food Chem.* 2009;57:1084–1092.
57. Raneva V, Shimasaki H, Ishida Y, Ueta N, Niki E. Antioxidative activity of 3, 4-dihydroxyphenylacetic acid and caffeic acid in rat plasma. *Lipids.* 2001;36:1111.
58. Déprez S, Mila I, Scalbert A. Carbon-14 biolabeling of (+)-catechin and proanthocyanidin oligomers in willow tree cuttings. *J Agric Food Chem.* 1999;47:4219–4230.
59. Cunha-Vaz JG. The blood–retinal barriers system. Basic concepts and clinical evaluation. *Exp Eye Res.* 2004;78:715–721.
60. Murthy KR, Goel R, Subbannayya Y, et al. Proteomic analysis of human vitreous humor. *Clin Proteomics.* 2014;11:29.
61. Breazzano MP, Fang H, Robinson MR, Abraham JL, Barker-Griffith AE. Vitreomacular attachment ultrastructure and histopathological correlation. *Curr Eye Res.* 2016;41:1098–1104.
62. Fincham GS, James S, Spickett C, et al. Posterior vitreous detachment and the posterior hyaloid membrane. *Ophthalmology.* 2018;125:227–236.
63. Garcia GA, Khoshnevis M, Yee KMP, et al. The effects of aging vitreous on contrast sensitivity function. *Graefes Arch Clin Exp Ophthalmol.* 2018;256:919–925.
64. Lobo A, Lightman S. Vitreous aspiration needle tap in the diagnosis of intraocular inflammation. *Ophthalmology.* 2003;110:595–599.
65. Pesudovs K. Patient-centred measurement in ophthalmology—a paradigm shift. *BMC Ophthalmol.* 2006;6:25.